



## PATIENT

Rusty Benzin

## SPECIES

Feline

## BREED

DSH

## SEX

Male Neutered

## AGE

11.10 years

## WEIGHT

9.4lbs

## INTERPRETED BY

Maggie Machen Lamy,  
DVM, DACVIM  
(Cardiology)

## IMAGING PERFORMED BY

T. Tenorio, DVM

## PRESENTING CLINICAL SIGNS

History: Rusty presented for a dental cleaning today and a grade III/VI sternal systolic heart murmur was ausculted. Murmur was not present 2 months ago. Owners noted that Rusty has seemed depressed for the past couple of weeks and has been less active. Rusty is FIV positive and takes prednisolone EOD to manage allergies. CBC/Chem was normal.

## ECHOCARDIOGRAM FINDINGS

2D, m-mode, color flow and doppler imaging is available. The left ventricular wall is asymmetric with mild septal thickening. There is a mildly hyperechoic endocardium consistent with fibrosis. Mild symmetric papillary muscle hypertrophy and remodeling. The right ventricle is subjectively normal in size and morphology. There is no left atrial enlargement present. No right atrial enlargement present. Normal RVOT velocity. Trace TR. Normal LVOT velocity. There is no obvious systolic anterior motion (SAM) of the mitral valve present. No MR. There is no pericardial effusion noted. No pleural effusion appreciated. No obvious cardiac tumors.

## CARDIAC CHART

FELINE CARDIAC PARAMETERS	BODY WEIGHT (kg)	HR (BPM)	IVSd (cm) <small>(Moise, Pipers)</small>	LVIDd (cm) <small>(Moise, Pipers)</small>	LVWd (cm) <small>(Moise, Pipers)</small>	FS (%)	EF (%)
NORMAL PARAMETER	-----	150-240	0.35-0.55	<2 (mean 1.5)	3.5-0.55	35-67	80-100
PATIENT	4.3	NM	0.67	1.1	0.51	63	94
FELINE CARDIAC PARAMETERS	LA/AO <small>(Boon)</small>	LA/AO HEART BASE (Swe) <small>(Abbott)</small>	LA 2D short axis Base view (cm) <small>(Abbott)</small>		LVOT VEL  (m/s)	RVOT VEL  (m/s)	E max  (m/s)
NORMAL	<1.5	<1.3	<1.2		<1.6	<1.3	<0.9
PATIENT	1.4	1.2	1.1		1.0	0.8	NM

*\*Note: All measurements based upon multi-modal images and methods. An average value is reported.*  
Adapted from June Boon, Veterinary Echocardiography, 1998  
Abbott J & MacLean H JVIM 2006;20: 111-119, Moise et al. Am J Vet Res 47:1476, 1986. Pipers et al. Am J Vet Res 40:882, 1979.

## HOSPITAL NAME

Wauwatosa Vet

## REFERRING VET

Dr. Oakes

## INVOICE

23997

## DATE

5/3/22

## INTERPRETATION OF THE FINDINGS & FURTHER RECOMMENDATIONS

Hypertrophic cardiomyopathy (HCM) is a rule out diagnosis once a patient is deemed normotensive and euthyroid. Both should be ruled out in this case as contributing factors. The degree of disease is mild, with only septal thickening and no LA dilation. This would indicate the risk for clinical issues is low at this time. No cause of the murmur is identified in this study, making it likely physiologic in origin. No additional issues are identified.

No medications are indicated prior to significant atrial dilation. It is important to note that no medications have been shown to definitively alter long term outcome at this stage, particularly in the absence of SAM.

Monitor at home for any respiratory issues or signs of blood clot events (neurologic change, paralysis, etc.). Anesthetic risk is considered mild, however judicious fluid administration is advised if needed with careful RR/RE monitoring to screen for fluid overload. Additionally, drugs that stimulate heart rate should be avoided unless clinically necessary (glycopyrrolate, atropine).



**PATIENT**

Rusty Benzin

Risk for complication with steroid use typically follows LA dilation, which in this case is mildly elevated. If needed, monitoring of RR/RE is advised particularly in the initiation phase.

**SPECIES**

Feline

**PLAN**

A screening blood pressure and T4 are recommended, then every 6 months lifelong.

**BREED**

DSH

A recheck echocardiogram is recommended in 6 months to assess for progression, sooner if any issues arise in the interim.

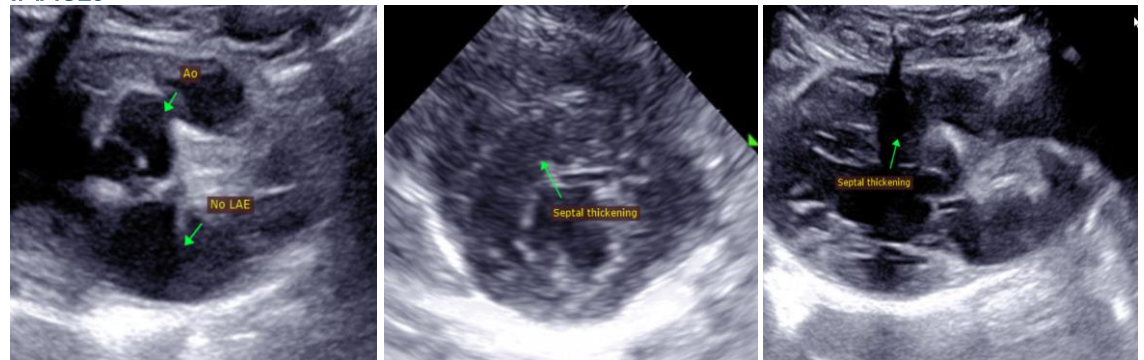
**SEX**

Male Neutered

**IMAGES**

**AGE**

11.10 years



**WEIGHT**

9.4lbs

The information and recommendations provided are based on the images presented by the referring veterinarian. No evaluation can be communicated regarding pathology that was not visible in the image/video clips provided.

**INTERPRETED BY**

Maggie Machen Lamy,  
DVM, DACVIM  
(Cardiology)

Thank you for this referral. This report was generated using transcription software, and minor dictation errors may be present. If the clinical or image interpretation does not parallel your findings or if I can be of any further assistance, please contact me.

**IMAGING PERFORMED BY**

T. Tenorio, DVM

Maggie Machen Lamy, DVM  
Diplomate of the American College of Veterinary Internal Medicine (Cardiology)  
info@sonopath.com

**HOSPITAL NAME**

Wauwatosa Vet

**REFERRING VET**

Dr. Oakes

**INVOICE**

23997

**DATE**

5/3/22